

Research Journal of Pharmaceutical, Biological and Chemical Sciences

Cytopathological Spectrum Of Thyroid Lesions: A Hospital Based Study.

R Akila*.

Assistant Professor Department Of Pathology, Thanjavur Medical College, Thanjavur. 613004, Tamil Nadu, India.

ABSTRACT

The thyroid gland lesions are common presentation in clinical practice. This study is a small attempt to evaluate the morphology of thyroid lesions using fine needle aspiration cytology as a diagnostic tool and was reported using Bethesda system of reporting thyroid cytology. The study was done on 100 patients in our hospital who presented with palpable thyroid lesions. The sensitivity, specificity and the diagnostic accuracy was done. Our study concluded that benign thyroid lesions are most common with Autoimmune thyroiditis being the predominant pathology reported here and brings to focus the change in scenario of the cytopathological spectrum of thyroid lesions from iodine deficient colloid goitre to Auto-immune based Thyroiditis.

Keywords: Bethesda, Thyroid gland lesions, Cytopathology.

<https://doi.org/10.33887/rjpbc/2023.14.5.42>

**Corresponding author*

INTRODUCTION

Diseases of the thyroid gland are commonly encountered in clinical practice and comprise a spectrum of entities which cause systemic diseases like Autoimmune thyroiditis, a localised lesion such as colloid goiter or a tumor mass. Prompt accurate diagnosis and early management help in reducing the morbidity and mortality associated with the thyroid pathology. The significance of the study lies in bringing to focus the change in scenario of the variation in thyroid pathology in the recent years. This is an attempt to evaluate the spectrum of various thyroid lesions using cytopathology which is a simple and non-interventional method of study [1-16].

Aims And Objectives

- To evaluate the morphology of the thyroid lesions by fine needle aspiration cytology in adult patients with swelling of the thyroid gland.
- To study the distribution of lesions according to age and sex.
- To correlate cytomorphological features of the thyroid gland lesions with histopathological features wherever possible.
- To evaluate sensitivity, specificity and diagnostic accuracy of different lesions.

Source And Data For The Material And Methods

The present study was conducted at the Department of Pathology in integration with Department of surgery, Thanjavur medical college, Thanjavur during the period - March 2022 to December 2022.

Sample Size: 100 cases

Inclusion Criteria: Adult patients with palpable thyroid gland enlargement attending the out and in - patient department in our hospital at Thanjavur medical college, department of pathology, integration with department of general surgery, Thanjavur medical college

Exclusion Criteria: Children with thyroid enlargement below 12 years of age.

MATERIALS AND METHOD

After explaining about the procedure and getting his/her written consent, the Fine needle aspiration of the thyroid gland was performed. The smears were stained using Hematoxylin and Eosin, Giemsa and Papanicolaou stains and interpreted using Bethesda System of Reporting Thyroid Cytopathology (BSRTC).

RESULTS AND DISCUSSION

Table 1: Distribution according to Bethesda classification in FNAC (n=100)

Bethesda category	Frequency	Percent
1 (ND/UNS)	5	5.0
2 (BN)	82	82.0
3 (AUS/FLUS)	2	2.0
4 (FN/SFN)	4	4.0
5 (SM)	4	4.0
6 (M)	3	3.0
Total	100	100.0

Comments: About 82% of the subjects belonged to category 2 in Bethesda classification of cytopathological examination while 4% each were in category 4 and category 5. Malignant lesions (category 6) were seen in 3% and 2% of subjects were classified as category 3 with atypia of undetermined significance.

Figure 1: Distribution according to Bethesda classification in FNAC (n=100).

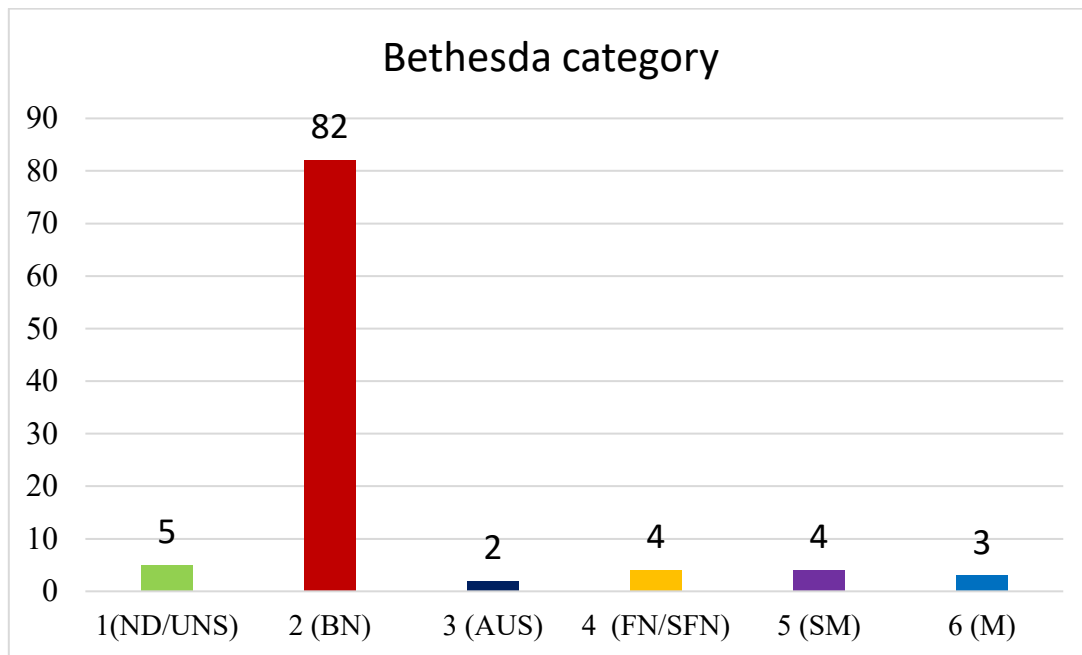


Table 2: Distribution of the thyroid lesions according to age and Bethesda classification in FNAC (n=100)

Age group	Bethesda category						Total
	1	2	3	4	5	6	
11 -20 years	1	5	0	0	0	0	6
21 to 30 years	0	12	0	2	0	2	16
31 - 40 years	2	26	1	1	1	0	31
41 - 50 years	1	23	1	1	1	0	27
51 - 60 years	1	11	0	0	0	1	13
>60 years	0	5	0	0	2	0	7
Total	5	82	2	4	4	3	100

Comments: Majority of the thyroid lesions belonged to category 2 (82%) in Bethesda classification of cytopathological examination which was common between 31 to 50 years (49%).

Table 3: Distribution of the individual thyroid lesions according to Bethesda classification in FNAC (n=100)

Bethesda category	Number of cases n (%)	Cytological diagnosis	Number of cases n (%)
1	5 (5)	ND/UNS	5 (5)
2	82 (82)	Colloid goiter/ Multinodular goitre	50 (50)
		Autoimmune thyroiditis (hashimoto's thyroiditis)	30 (30)
		Granulomatous thyroiditis	2 (2)
3	2 (2)	Atypia of undetermined significance (AUS)	2 (2)
4	4 (4)	Follicular neoplasm	2 (2)
		Suspicious of Follicular neoplasm	2 (2)
5	4 (4)	Suspicious of papillary carcinoma	3 (3)
		Suspicious of Malignancy	1 (1)
6	3 (3)	Papillary carcinoma	2 (2)

		Poorly differentiated carcinoma	1 (1)
Total	100 (100)		100 (100)

Comments: Colloid goiter/ Multinodular goiter was the commonest lesion (50%) followed by hashimoto's thyroiditis (30%). Category 4, 5 and 6 together accounted for 11% only.

Figure 2: Distribution of the individual thyroid lesions according to Bethesda classification in FNAC (n=100)

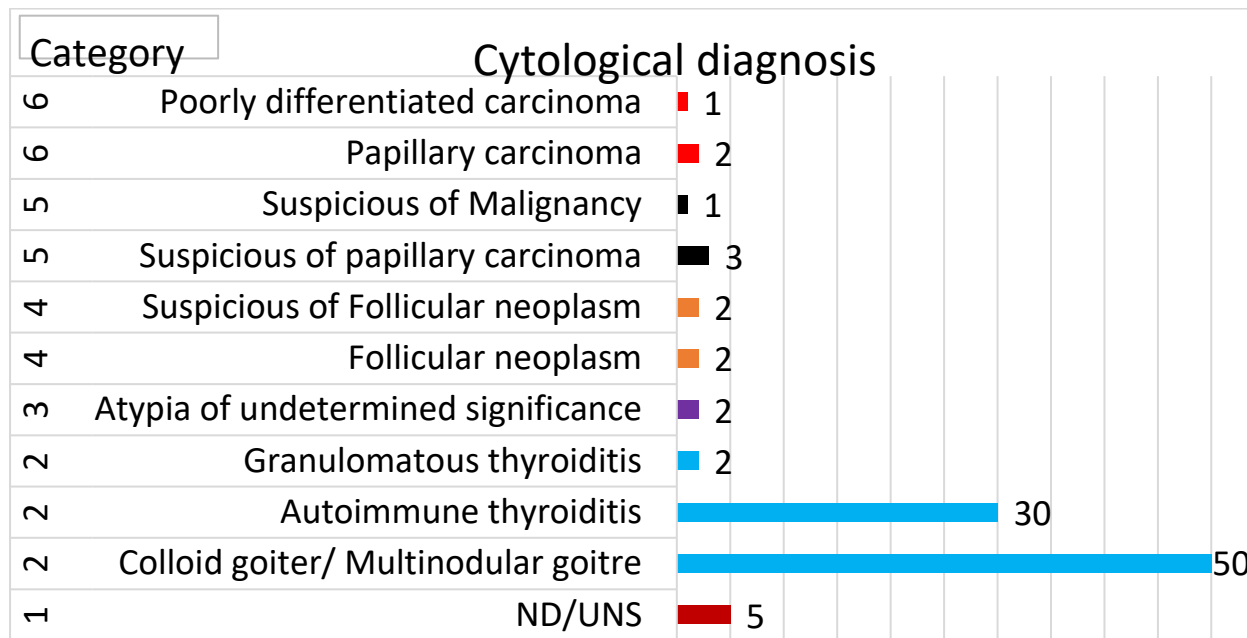


Table 4: Comparison of cytological diagnosis with various studies (n=100)

Bethesda category (%)	Research study					
	Current study	Prathima et al	Bhagat et al	Sinna et al	Shankar SP et al	Mondal SK et al
1 (ND/UNS)	5	11.7	5.6	7.1	10.7	1.2
2 (BN)	82	77.5	87.5	33.1	81.6	87.5
3 (AUS)	2	1.12	15	13.5	1.2	1
4 (FN/SFN)	4	3.9	3.1	16.5	1.7	4.2
5 (SM)	4	2.2	0.6	10.1	2	1.4
6 (M)	3	3.3	3.1	19.5	2.7	4.7

Comments: The high proportion of category 2 lesions observed in the current study was comparable with almost all the studies except for Sinna et al. The proportion of follicular and papillary neoplasm also correlated with the findings of other study [17-22].

Figure 3: Comparison of cytological diagnosis with various studies (n=100)

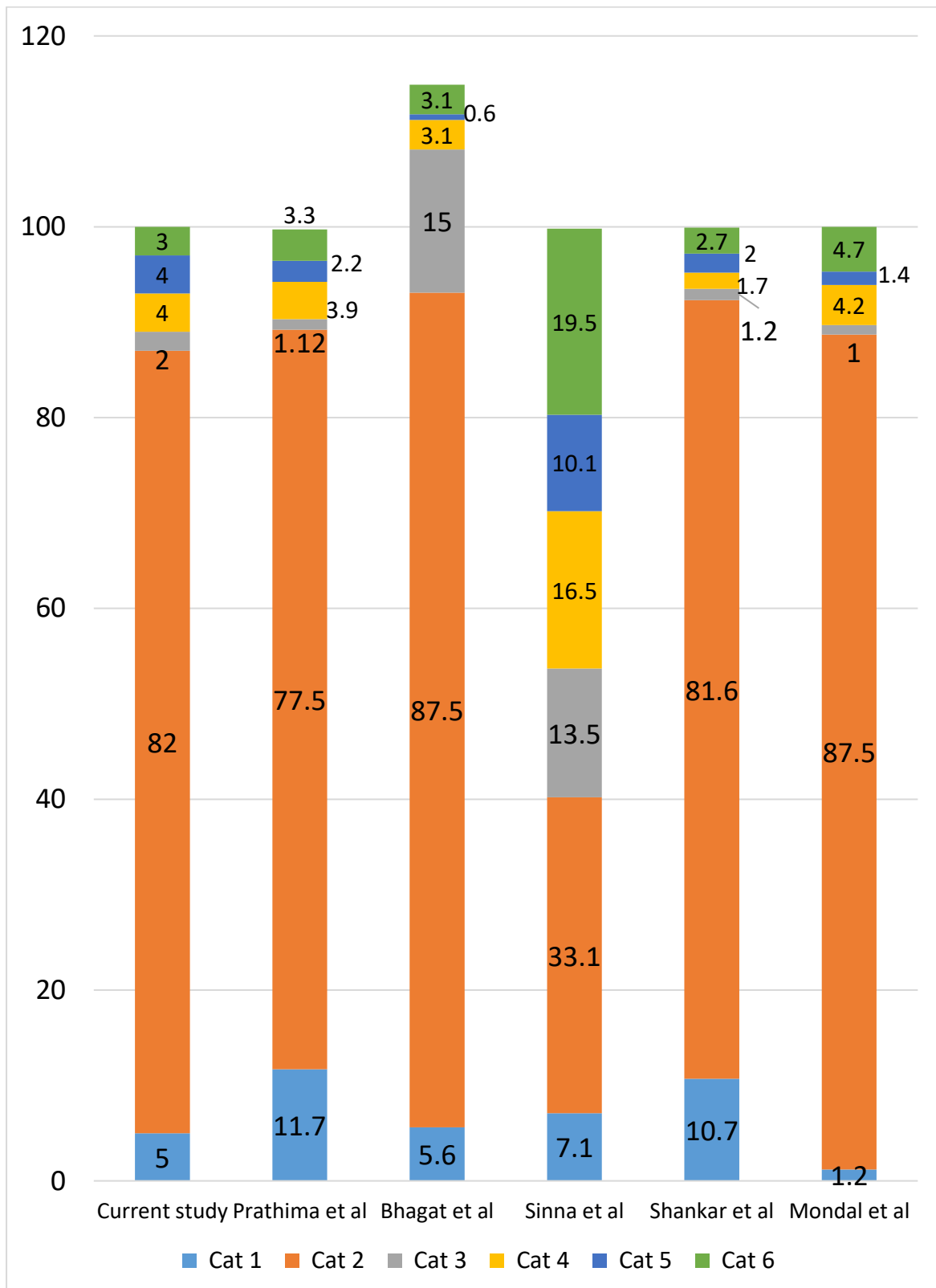


Table 5: Distribution of the individual thyroid lesions subjected to histopathology according to Bethesda classification in FNAC

Bethesda category	Number of cases in FNAC n (%)	Histopathology done n (%)
1 (ND/UNS)	5 (5)	0 (0)
2 (BN)	82 (82)	20 (74.1)
3 (AUS/FLUS)	2 (2)	1 (3.7)
4 (FN/SFN)	4 (4)	2 (7.4)
5 (SM)	4 (4)	2 (7.4)
6 (M)	3 (3)	2 (7.4)
Total	100 (100)	27 (100)

Comments: The high proportion of category 2 lesions accounted for high portion (74.1%) of the thyroid lesions subjected to histopathology. Two lesions each from category 4,5 and 6 were subjected to histopathology.

Table 6: Distribution of the thyroid lesions according to histopathology & Bethesda classification in FNAC (n=27)

Bethesda category	No. of cases n (%)	Cytological spectrum of lesions	Number of cases n (%)
2	20 (74.1)	Colloid goiter/ Multinodular goiter	15 (55.6)
		Autoimmune thyroiditis (hashimoto's thyroiditis)	2 (7.4)
		Papillary carcinoma	1 (3.7)
		Follicular adenoma	1 (3.7)
		Hyperplastic colloid nodule	1 (3.7)
3	1 (3.7)	Follicular carcinoma	1 (3.7)
4	2 (7.4)	Colloid goiter/ Multinodular goitre	1 (3.7)
		Papillary carcinoma	1 (3.7)
5	2 (7.4)	Papillary carcinoma	2 (7.4)
6	2 (7.4)	Papillary carcinoma	2 (7.4)
Total	27 (100)		27 (100)

Comments: Atleast one malignant lesion was found in thyroid lesions subjected to histopathology from all the Bethesda categories except category 1 as no lesion in that category was subjected to histopathological examination.

Table 7: Relation between cytological and Histological diagnosis (n=26)

Category	Histopathology		Total
	Neoplastic	Non-neoplastic	
2	18 (FN)	2 (TN)	20
4	2 (TP)	0 (FP)	2
5	2 (TP)	0 (FP)	2
6	2 (TP)	0 (FP)	2
Total	24	2	26

Sensitivity = $6/24 = 25\%$, Specificity = $2/2 = 100\%$

Positive predictive value (PPV) = $6/6 = 100\%$

Negative predictive value (NPV) = $2/20 = 10\%$

Comments: In the current study, specificity and positive predictive value of cytological diagnosis according to Bethesda system was 100% but the sensitivity and negative predictive value was 25% and only 10% respectively. This is primarily because of the occurrence of high number of false negatives in category 2 of cytological diagnosis. Hence, it can be stated that Subjects reported to be suspicious of follicular neoplasm (cat 4), suspicious of malignancy (Cat 5) and malignant lesions (Cat 6) almost always had neoplastic lesions in histological diagnosis. Furthermore, the sample size is relatively small to generalize these results.

The result of this study is representative of the thyroid pathology presenting in this study population .

- A total of 100 cases with thyroid enlargement were subjected to fine needle aspiration cytology. Out of these, twenty seven cases had histopathological evaluation of their surgically removed thyroid.
- Using the gold standard technique - Fine Needle aspiration cytology which is a simple, safe, cost effective technique the cytopathological spectrum of the thyroid lesions was categorised using the standardized Bethesda system of reporting thyroid cytopathology and correlated with respective histopathological findings wherever possible.
- Age of the patients ranged from 18 to 80 years with a mean age being 41.3 years.
- Majority of the patients were females. Females-87% and Males 13% with a female to male ratio of 6.7 : 1 respectively.

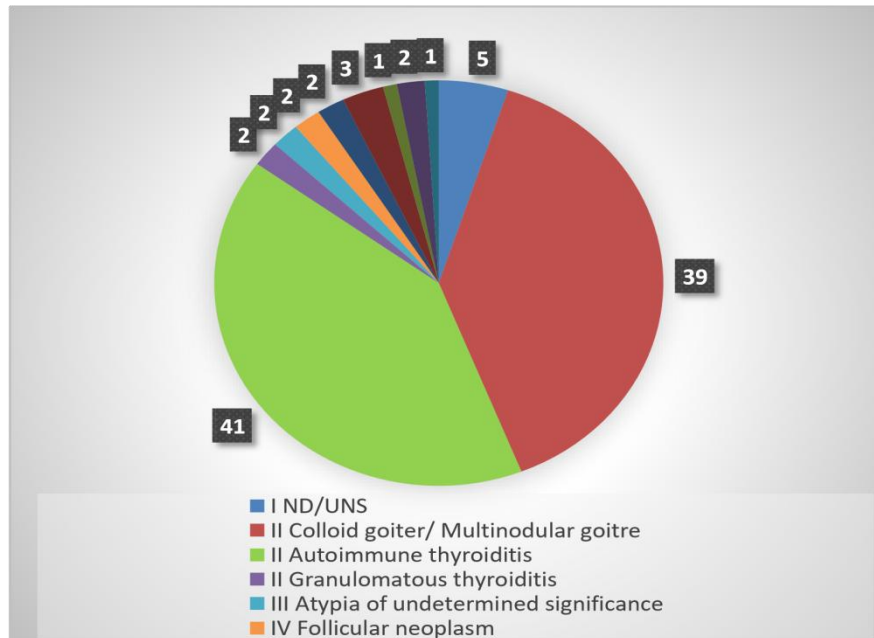
The cytological spectrum of the thyroid lesions in this study population as categorised using Bethesda system of reporting was as follows:

➤ Colloid Goitre / Nodular colloid Goitre	39%	CAT-II
➤ Hashimoto thyroiditis	30%	CAT-II
➤ Lymphocytic thyroiditis	11%	CAT-II
➤ Granulomatous thyroiditis	2%	CAT-II
➤ Atypia of undetermined significance	2%	CAT-III
➤ Suspicious of Follicular neoplasm	2%	CAT-IV
➤ Suspicious of Papillary carcinoma -	3%	CAT-IV
➤ Follicular neoplasms	2%	CAT-IV
➤ Suspicious of malignancy	1%	CAT-V
➤ Papillary carcinoma	2%	CAT-VI
➤ Poorly Differentiated carcinoma	1%	CAT-VI

- In the present study , Autoimmune thyroiditis (41%) was found to be the commonest thyroid pathology to be diagnosed cytologically, it was followed by Colloid goiter (39%).
- On cytology we reported one case as "Suspicious of Papillary carcinoma" which on histopathology was confirmed to be "Warthin tumor-like variant of Papillary Carcinoma" a very rare entity.
- Another interesting observation was of a case with long standing history of thyroid enlargement which was reported as "Follicular lesion of undetermined significance" on FNAC but turned out to be "Follicular carcinoma with Hurthle cell change" on histopathology.

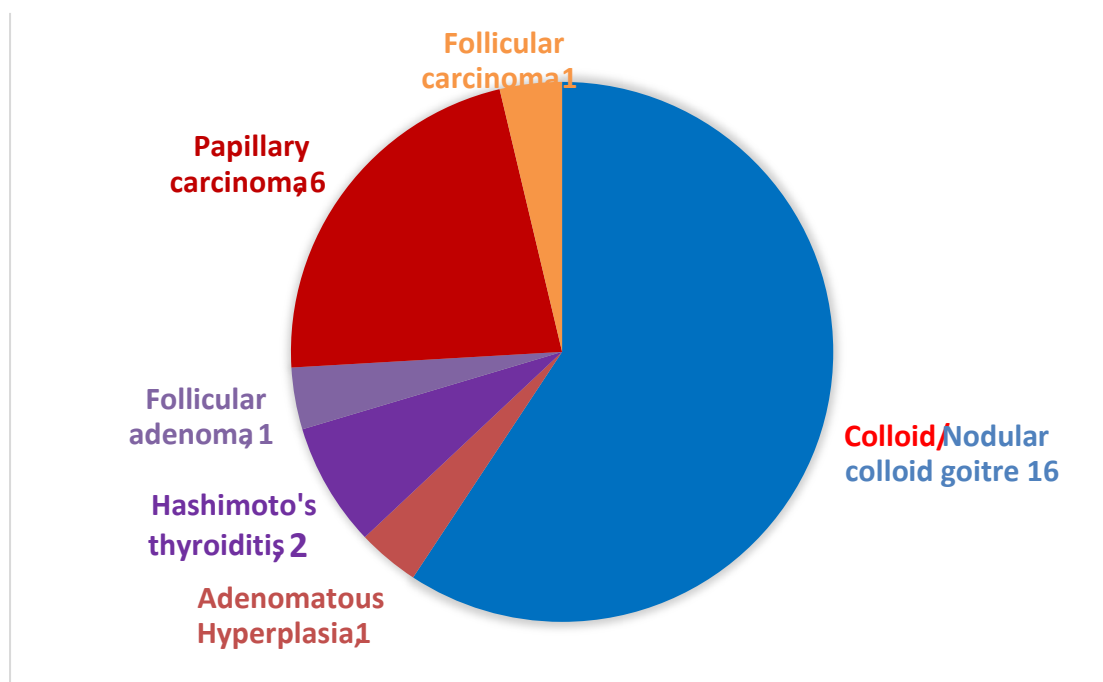
- Among the malignant lesions reported on cytology, Follicular and Papillary neoplasms were of equal proportion.

Figure 4: Spectrum of thyroid lesions in FNAC (n=100)



Out of the 100 cases subjected to thyroid cytology, 27 patients had surgical resection of their thyroid which revealed a spectrum of lesions on histopathology : Colloid goitre/Nodular colloid goiter, Adenomatous hyperplasia, Hashimoto's thyroiditis, Follicular adenoma, Follicular carcinoma and Papillary carcinoma.

Figure 5: Spectrum of thyroid lesions on Histopathology (n=27)



- Among the thyroid lesions confirmed by histopathology, Colloid / Nodular colloid goitre was the commonest (59%) followed by Papillary carcinoma (22%) and Hashimoto thyroiditis 7.4% respectively.
- Risk of malignancy on surgical resection for FNA thyroid diagnostic categories using TBSRTC was found to be as follows:
- CAT-I -0%, CAT II -5%, CAT IV-50% , CAT III,V and VI 100%.
- Cytological and histopathological correlation revealed that 81% of the lesions were concordant.
- The specificity and the positive predictive value was 100%.
- Sensitivity and negative predictive value was 25% and 10%. This is primarily because of the occurrence of high number of false negatives in category II on cytological diagnosis. Furthermore, the sample size is too small which is the limitation of our study [18-40].

CONCLUSION

The present study concludes that in our study population, Benign lesions of the thyroid are the most common based on Fine needle aspiration cytology with Autoimmune (Hashimoto's) thyroiditis being the predominant pathology reported here.

This study brings to focus the recent change in the scenario of the cytological spectrum of thyroid lesions i.e a shift from Iodine-deficient Colloid goitres to Autoimmune-based Thyroiditis.

In view of the fact that Hashimoto thyroiditis shows marked clustering with other auto immune diseases, it is strongly recommended that all cases with thyroid enlargement should undergo Autoantibody study along with the routine thyroid hormonal screening, clinical follow up and intermittent FNAC to reduce the incidence of associated morbidity.

REFERENCES

- [1] Santosh Kumar Mondal, Simanti Sinha, Bijan Basak, Dipanwita Nag Roy and swapan Kumar Sinha. The Bethesda System of reporting Thyroid fine needle aspirates: A cytological study with histological follow up. J cytol.2013.Apr-June;30(2);94-99.
- [2] Kamaljit Kaur, Nishisonkhya A.S.Bapna, Pradeep Mital. A comparative study of FNAC, ultrasound and radionuclide scan in the management of solitary thyroid nodule: A prospective analysis of 50 cases.IJO and head and neck surgery 2002;54(2):96-101.
- [3] Sternberg's diagnostic surgical pathology. Stancey E. Mills, zubair W Baloch, Virginia A.Livolsi; Fifth edition pp: 493-535
- [4] A.Deniwar,et al., Examining the Bethesda criteria risk stratification of Thyroid nodules Pathol. - Pathology research and practice-2015
- [5] Yoon Yang Jung, Sejin Jung, Hyun Lee, Young Lyun Oh, Acta Cytologica 2015;59;370-376
- [6] Orell SR et al. Manual and atlas of FNAC-5th Edition. Thyroid Edinberg Churchill Livingstone;2012;pp 118-120.
- [7] Jack Yang,Vicki schnadig,Roberto Logrono,Patrica G.Wassermann. Fine needle aspiration of Thyroid nodules: A study of 4073 patients histological and clinical correlations; Cancer Cytopath vol 111/Number 5,october,2007
- [8] Jiyeon Hyeon, Soomin Ahn, Jung Hee Shin, Young Lyun oh; The prediction of malignant risk in the category Atypia of undetermined significance/Follicular lesion of undetermined significance of Bethesda system of reporting thyroid cytology using Sub categorization and BRAF mutation result; Cancer cytopathology 2014 May.
- [9] E.A.Sinna, N.Ezzat. Diagnostic accuracy of fine needle aspiration cytology in thyroid lesions. Journal National Cancer Institute (2012)24,63-70
- [10] Constantine G.A.Theoharis, Kevin M.schofield, Lynwood Hammers, Robert N and David C.Chieng. The Bethesda fine needle aspiration classification system. Thyroid cancer and nodules; Thyroid vol:19;11/2009.
- [11] A short history of the thyroid gland ;V. Leoutsakos Dept of Surgery Athens University School of Medicine, Athens, 115 27 Greece
- [12] Textbook of Human Histology with colour atlas and practical guide-Sixth edition;Inderbir singh ;Pg 325-327
- [13] Hoyes AD, Kershaw DR. Anatomy and development of the thyroid gland. Ear, Nose Throat J 1985;64: 318-333.

- [14] Histology A text and Atlas with correlated cell and molecular biology; sixth edition: Michael H.Ross; Wojciech Pawlina: Pg 755-760.
- [15] Rosai and Ackerman's Surgical Pathology; Juan Rosai: Tenth edition:Pg:488-538.
- [16] Ohri AK, Ohri SK, Sing MP. Evidence for thyroid development from the fourth branchial pouch. J Laryngol Otol 1994;108:71-73.
- [17] Sugiyama S. The embryology of the human thyroid gland including ultimobranchial body and others related. Adv Anat Embryol Cell Biol 1970;44:6-110.
- [18] Mansberger AR Jr, Wei JP. Surgical embryology and anatomy of the thyroid and parathyroid glands. Surg Clin North Am 1993; 73(4):727-746.
- [19] Sinnathamby c.s.thyroid gland 1999; pp330-332
- [20] Robbins and cotran pathologic basis of disease Eighth edition;Kumar;Abbas; Fausto ;Aster; chapter 24.
- [21] Harrisons principles of internal medicine 18 th edition;Chap:335
- [22] Hegedus L, Perrild H, Poulsen L, et al. The determination of thyroid volume by ultrasound and its relationship to body weight, age, and sex in normal subjects. J Clin Endocrinol Metab 1983;56: 260-263
- [23] Bailey and love's short practice of surgery -25 th edition
- [24] Townsend Beauchamp Evers Mattox Sabiston Textbook of Surgery;The biological basis of modern surgical practice; 18th ed.Chapter-36.
- [25] Dorairajan N, Pradeep PV. Vignette Thyroid Surgery: A Glimpse Into its History. International Surgery. 2013; 98(1):70-75. doi:10.9738/CC185.1.
- [26] Jason A, 1946 The thyroid gland in Medical History. New York Froben press
- [27] Merk F, 1984 History and iconography of endemic goitre and cretinism. Lancaster, England MTP Press
- [28] Niazi, Asfandyar Khan et al. "Thyroidology over the Ages." Indian Journal of Endocrinology and Metabolism 15.Suppl2 (2011): S121-S126. PMC. Web. 19 May 2017.
- [29] Langman's medical embryology;Ninth edition;pg:363-401
- [30] Stell and Maron's head and neck surgery 4th edition.
- [31] Difiores atlas of histology with functional correlations;Victor P. Eroschenko: Eleventh edition;Pg:395-401
- [32] Histology for pathologists; Third edition ;Stacy E.Mills;Pg:1130-1134
- [33] Text book of medical physiology :Eleventh edition:Guyton and Hall; Pg:931-943
- [34] Ganongs review of medical physiology twenty third edition;Kim E. Barret;Susan M.Barman;Scott Boitano;Heddwen L.Brooks:Chapter 20
- [35] koss's diagnostic cytology and its histological basis ;Fifth edition; Leopold G. Koss; Myron R.Melamed;Pg;1149-1182.
- [36] Bibo's comprehensive cytopathology Marluce Bibbo;David C.Wilbur;Third edition: Pg 626-657.
- [37] Orell and Sterrett's Fine needle aspiration cytology: Fifth edition: Svate R.Orell;Gregory F.Sterrett Pg118-149.
- [38] Greys Anatomy .The anatomical basis of clinical practice .fortieth edition;Pg:462-465
- [39] National Journal of basic medical sciences-Volume-IV,Issue-1Thyroid FNAC : Experience with Thyroid Bethesda system in practice; Amrit Kaur Kaler, Raja Parthiban, N.Gandhi,HTJ Prakash.
- [40] 40.Kendall CH.Fine needle aspiration of thyroid nodules. Three year experience J Clinical Path 1989;45:23-27